




Contents lists available at [SciVerse ScienceDirect](http://www.sciencedirect.com)

International Journal of Pediatric Otorhinolaryngology

journal homepage: www.elsevier.com/locate/ijporl



The effects of office-based frenotomy for anterior and posterior ankyloglossia on breastfeeding

Cliff O'Callahan^{a,*}, Susan Macary^b, Stephanie Clemente^c

^a Family Practice Residency Program, Middlesex Hospital, Middletown, CT, United States

^b Opportunity Knocks for Middletown's Young Children Collaborative, Family Advocacy Program, Middlesex Hospital, 28 Crescent Street, Middletown, CT 06457, United States

^c Department of Chemistry, Wesleyan University, Middletown, CT, United States

ARTICLE INFO

Article history:

Received 15 December 2012

Received in revised form 17 February 2013

Accepted 24 February 2013

Available online xxx

Keywords:

Ankyloglossia

Tongue-tie

Frenotomy

Breastfeeding

Pediatric primary care

Pediatric otorhinolaryngology

ABSTRACT

Objectives: The objectives of this study were to assess the effect of office-based frenotomy on reversing breastfeeding difficulties among infants with problematic ankyloglossia, and to examine characteristics associated with anterior and posterior ankyloglossia.

Methods: Mothers of infants who underwent a frenotomy for ankyloglossia from December 2006 through March 2011 completed a post-intervention web-based survey about breastfeeding difficulties they experienced before and after the frenotomy. Maternal-infant dyads had been referred from health providers to a primary care practice for assessment of ankyloglossia. Infants were subsequently classified as having no ankyloglossia, anterior (Type I or Type II) or posterior (Type III or Type IV).

Results: There were 311 infants evaluated for ankyloglossia and 299 (95%) underwent a frenotomy. Most infants were classified as having Type III (36%) or IV (49%) ankyloglossia compared to only 16% with anterior (Type I and Type II combined). Differences by classification type were found for gender ($P = .016$), age ($P = .017$), and maxillary tie ($P = .005$). Among survey respondents ($n = 157$), infant latching significantly improved ($P < .001$) from pre- to post-intervention for infants with posterior ankyloglossia. Both the presence and severity of nipple pain decreased from pre- to post-intervention among all classifications ($P < .001$). Additionally, 92% of respondents breastfed exclusively post-intervention. The mean breastfeeding duration of 14 months did not differ significantly by classification. **Conclusions:** Breastfeeding difficulties associated with ankyloglossia in infants, particularly posterior, can be improved with a simple office-based procedure in most cases. The diagnosis and treatment of ankyloglossia should be a basic competency for all primary care providers and pediatric otorhinolaryngologists.

© 2013 Elsevier Ireland Ltd. All rights reserved.

1. Introduction

Ankyloglossia, or tongue tie, refers to excessive sublingual frenular tissue resulting from incomplete separation of the tongue from the floor of the mouth during embryogenesis (apoptosis). Anterior ankyloglossia, also described as Type I and Type II ankyloglossia, is characterized by insertion at the tip of the tongue (Type I) or slightly behind the tip (Type II). Posterior ankyloglossia is characterized by a thickened frenulum (Type III) or a submucosal frenulum which is visualized as a flat, broad mound absent of any typical protruding frenular tissue, and restricts movement at the base of the tongue (Type IV) [1,2]. Most literature refers to the

anterior types and rarely reflects the existence and relevance of the posterior types [1,3].

Maxillary tie, also described as restrictive upper labial frenulum, and ankyloglossia in infants present with interference of breastfeeding, resulting in a characteristic set of maternal and infant symptomatology and physical findings [1,4]. In infants, ankyloglossia is most often manifest as maternal nipple pain, infant latching difficulties, and poor infant feeding and growth parameters. Infants with maxillary tie have a thicker frenulum that inserts into the papilla and restricts lip splay, resulting in a poor seal and inefficient feeding. These difficulties increase utilization of medical services, breast milk pumping, and accessory feeding methods, which often lead to breastfeeding cessation [5–7].

Numerous publications [3,8–15] exist to support the contention that frenotomy is simple, efficacious, and necessary in achieving the breastfeeding recommendations (i.e., to provide breast milk exclusively for the first six months of life and continued breastfeeding through the first year of life) established by the

* Corresponding author at: 90 South Main Street, Middletown, CT 06457, United States. Tel.: +1 860 358 6407; fax: +1 860 344 9249.

E-mail addresses: cliff.o'callahan@midhosp.org, cmocallahan@aap.net (C. O'Callahan).

American Academy of Pediatrics [16], U.S. Surgeon General [17], and World Health Organization [18].

Less well described in the literature is the distinction among infants with different types of ankyloglossia in relation to breastfeeding difficulties and response to frenotomy [3].

Our review of the literature suggests that most researchers primarily studied anterior ankyloglossia. We located only one case series that hinted at the importance of posterior ankyloglossia in relation to breastfeeding failure [3]. The objectives of our study were to assess the effect of office-based frenotomy among infants with problematic ankyloglossia on reversing breastfeeding difficulties and to elucidate differences among infants with anterior and posterior ankyloglossia.

2. Patients and methods

2.1. Study design

Women whose infants underwent a frenotomy from December 2006 through March 2011, were asked to complete an 18-item, web-based questionnaire about maternal-infant breast feeding characteristics before and after the intervention. The web-linked questionnaire was offered between December 2010 and May 2011, with three follow-up reminders. Infant date of birth, ankyloglossia classification, date of frenotomy, and referral source were gathered from chart review. The Middlesex Hospital Institutional Review Board approved this study.

2.2. Referral process

Referrals were made to a single, salaried pediatrician by lactation consultants, physicians, and craniosacral practitioners from central Connecticut and western Massachusetts for infant breastfeeding difficulties or failure to gain weight. Some infants were referred for a re-release of their frenulum which had been previously clipped at a different facility, but which provided no or little improvement in breastfeeding dynamics.

2.3. Ankyloglossia assessment

The pediatrician's assessments included maternal reports of breastfeeding difficulties, a generalized examination for infant difficulties looking for swallowing and neurological deficits, and a suck evaluation using a gloved finger in the infant's mouth. A suck evaluation characterizes the child's seal, suction, sensation of the tongue along the finger, and its ability to cup the finger. The infant's oral cavity was examined while in the "lap-to-lap" position by raising the child's tongue with cotton applicators to determine the thickness, extent, and insertion points of the sublingual frenulum, and the movement and shape of the tongue. Type IV ankyloglossia requires one to manually elevate the tongue in order to demonstrate the restrictive band or column of tissue that then protrudes, and the relative inability to raise the base of the tongue. These physical characteristics, combined with the symptoms of breast pain, shallow slipping-off latch, compression of the nipples, clicking, and inefficient feeds are what define a problematic tie and eligibility for sublingual frenotomy. Finally, the superior lip was lifted and determined to be problematic if the frenulum was thick, restrictive, and distally inserting at the papilla, combined with reports of poor splay at breast.

2.4. Intervention

Almost all infants received topical 20% benzocaine and three drops of 22% sucrose (*note*: as of April 7, 2011, the use of benzocaine in children under two years is no longer recommended

by the U.S. Food and Drug Administration; currently, only sucrose is administered). Infants were swaddled and immobilized, the head positioned in a slight sniffing position, and approached from a cephalad position for best visualization.

An open, stable operative field was achieved by using a metal grooved elevator held with the thumb and index fingers while the middle finger maintained pressure on the lower gum to keep the jaw open (reverse "chop-stick" maneuver). A blunt-tipped, curved scissors was used to clip the thin diaphanous membrane, if present; the mucosa at the thinnest part of the frenular protrusion near the underside of the tongue and; the shiny white submucosal band, if present. Gentle blunt dissection with a cotton tipped applicator opened the mucosa further. The desired result was a flat diamond-shaped opening of the mucosa at the base of the tongue.

Maxillary frenotomy consisted of lifting the infant's lip with a gauze and clipping parallel to the gum by 3–4 mm (*note*: the current technique includes making a crush line parallel to the gum with a wide clamp and then cutting through the crushed tissue) (Fig. 1).

Hemostasis was achieved by applying direct pressure using gauze for 2–4 min. Three infants required cauterization with silver nitrate to stop persistent oozing. Sutures, Gelfoam or the direct application of a drop of 1:1000 epinephrine (all part of an emergency kit) were never required. Thereafter the infant was brought to breast or bottle.

2.5. Statistical analysis

Categorical data were analyzed using Pearson's chi-square analysis and, when appropriate, Mantel-Haenszel chi square, Fisher's Exact or McNemar's Exact tests. Comparisons of non-parametric, continuous data were analyzed using Mann-Whitney or Kruskal-Wallis tests. Changes in the level of maternal breast pain from pre- to post-intervention were analyzed using the Sign test. For all tests, $P < .05$ was considered statistically significant. IBM SPSS Statistics version 19 was used for data analysis.

3. Results

3.1. Characteristics of all treated infants

Characteristics of all treated infants are shown in Table 1. There were 311 infants evaluated for ankyloglossia and 299 (95%) underwent a frenotomy. Twelve infants did not undergo the

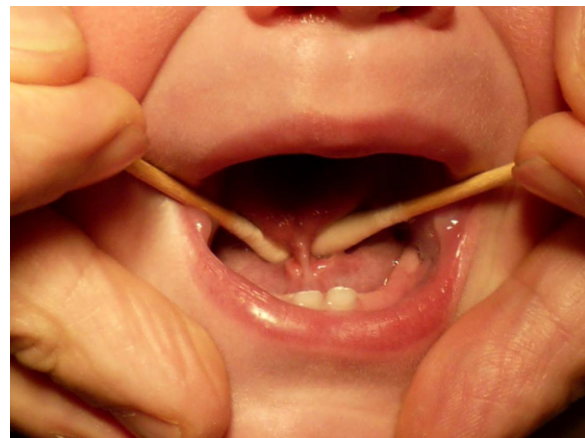

Fig. 1. An example of a two-month-old child with Type III ankyloglossia. Note the thick white non-elastic frenulum accentuated between the cotton tipped applicators that are lifting the tongue.

Table 1
 Characteristics of all treated infants with ankyloglossia.

	Total	Ankyloglossia classification			P ^a
		Anterior (Type I and Type II)	Type III	Type IV	
Total	299	47 (16)	107 (36)	145 (49)	
Median infant age (days)	35	24	35	41	.017 ^b
Infant age (days), n (%)					.100 ^c
2–30	131 (44)	31 (61)	48 (42)	52 (31)	
31–60	89 (30)	6 (22)	28 (25)	55 (43)	
61–90	36 (12)	2 (0)	14 (17)	20 (17)	
91–323	43 (14)	8 (17)	17 (15)	18 (9)	
Infant gender, n (%)					.016
Male	162 (51)	32 (68)	63 (59)	67 (46)	
Female	137 (49)	15 (32)	44 (41)	78 (54)	
Maxillary tie, n (%)					.005
Yes	72 (37)	7 (21)	21 (30)	44 (48)	
No	124 (63)	27 (80)	50 (70)	47 (52)	

^a Pearson chi-square.
^b Kruskal–Wallis.
^c Mantel–Haenszel chi-square.

procedure due to parental choice or a determination of an alternative explanation. Fifty-four percent of infants who received the procedure were male. The median age at the time of the frenotomy was 35 days (range, 2–323 days).

The majority of infants were classified as having either Type IV (49%) or Type III (36%) ankyloglossia compared to Type II (12%) and Type I (3%). Males accounted for 68% of infants with anterior ankyloglossia compared to 59% with Type III and 46% with Type IV ($P = .016$). Infants with Type IV ankyloglossia had a higher median age (41 days) compared to those with Type III (35 days) and those with anterior (24 days) ($P = .017$). Maxillary tie was present in 37% of infants, including nearly half (48%) with Type IV ankyloglossia compared to Type III (30%) and anterior (21%) ($P = .005$) (Fig. 2).

Comparisons between survey respondents and non-respondents are shown in Table 2. A post-treatment survey was completed by 157 mothers for a response rate of 53%. Infants of survey respondents were more likely than non-respondents to have a Type IV ankyloglossia classification (55% vs. 41%) but less likely to have Type III (33% vs. 39%) or anterior (12% vs. 20%) ($P = .021$). Survey respondents were also more likely than non-respondents to have infants with maxillary tie (44% vs. 29%, $P = .024$). Infant age and gender did not differ significantly by survey response group.

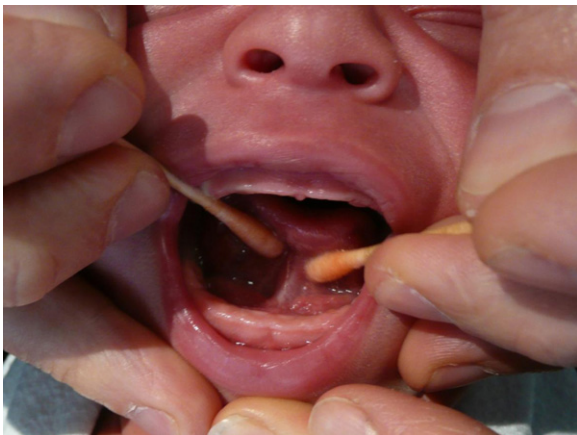

Fig. 2. A one-month-old child with Type IV ankyloglossia. Note the wide midline hump with its white submucosal sheen that is restricting tongue lift between the cotton applicators.

3.2. Characteristics of treated infants among survey respondents

Characteristics of treated infants among survey respondents are shown in Table 3. Half (51%) of respondents had male infants and this differed significantly by ankyloglossia classification. Seventy-two percent of infants with anterior ankyloglossia were male compared with 60% of those with Type III and only 41% of those with Type IV ($P = .018$). Maxillary tie was present in 44% of infants, but this also differed by classification type. None of the infants with anterior ankyloglossia had maxillary ties compared to 42% of those with Type III and 56% of those with Type IV ($P = .001$).

Among the 27% of infants who had multiple frenotomies, including the index surgery, 38% had pre-index frenotomies performed by another provider, and 27% had post-index frenotomies performed by another provider. The pediatrician performed both the index surgery and a subsequent frenotomy on 36% of infants. There were no significant differences among classification types.

Breastfeeding consultation prior to the frenotomy consultation was sought by nearly all respondents (98%) and did not differ significantly by ankyloglossia classification. Most respondents (93%) had maternal breastfeeding difficulties which significantly varied among infants with Type III (98%), Type IV (93%) and anterior (78%) ankyloglossia ($P = .030$). Nearly all respondents (99%) had infant breastfeeding difficulties, including all infants with Type III and Type IV ankyloglossia and 94% with anterior, but this difference was not statistically significant.

Pre- and post-intervention infant latching difficulties and maternal nipple pain responses are shown in Table 4. Half of the respondents for whom latching issues were the presenting problem reported no issues after the intervention. No new latching issues emerged ($P < .001$). This pattern of improved latching and no deterioration in latching post-intervention persisted for infants with Type III and Type IV ankyloglossia ($P < .001$), and the difference for anterior ankyloglossia infants was not statistically significant.

Sixty-four percent of the 118 respondents who reported nipple pain while breastfeeding prior to the intervention reported no nipple pain one week post-intervention ($P < .001$). This pattern of decreased nipple pain and no new nipple pain post-intervention persisted for all ankyloglossia classification types ($P < .001$). All respondents either stayed the same or had improvements in their severity of nipple pain as well ($P < .001$).

Exclusive breastfeeding was reported by nearly all respondents (92%) post-intervention. The mean duration of breastfeeding was

Table 2
Characteristics of treated infants between survey respondents and non-respondents (N=299).

	Survey respondents	Survey non-respondents	P ^a
Total	157	142	
Median infant age (days)	41	31	.169 ^b
Infant age (days), n (%)			.465 ^c
2–30	60 (38)	71 (50)	
31–60	54 (35)	35 (25)	
61–90	24 (15)	12 (9)	
91–323	19 (12)	24 (17)	
Infant gender, n (%)			.239
Male	80 (51)	82 (58)	
Female	77 (49)	60 (43)	
Ankyloglossia classification, n (%)			.021
Anterior (Type I and Type II combined)	18 (12)	29 (20)	
Type III	52 (33)	55 (39)	
Type IV	87 (55)	58 (41)	
Maxillary tie, n (%)			.024
Yes	44 (44)	28 (29)	
No	55 (56)	69 (71)	

^a Pearson chi-square.^b Mann–Whitney U.^c Mantel–Haenszel chi-square.

14 months (SD: 10.2 [range 0.5–54 months]) and did not differ significantly by ankyloglossia classification (table not included). Ten respondents were still breastfeeding at the time of the survey and 46 respondents did not provide data about duration of breastfeeding. Finally, most respondents reported no complications or negative side effects resulting from the frenotomy (94%), and that undergoing the frenotomy was worth the emotional and physical discomfort to themselves and their infants (93%).

4. Discussion

The vast majority of problematic breastfeeding problems are corrected by hospital-based and community lactation consultants with well established techniques of positioning. Only a small fraction of dyads seen by consultants were referred for what they felt was ankyloglossia. Thus, the majority of infants in our study presented with persistent breast feeding difficulties that resisted

Table 3
Characteristics of treated infants among survey respondents.

	Total	Ankyloglossia classification			P ^a
		Anterior (Type I and Type II)	Type III	Type IV	
Total	157	18	52	87	
Median infant age (days)	41	22	35	42	.107 ^b
Infant age (days), n (%)					.045 ^c
2–30	60 (38)	11 (61)	23 (42)	27 (31)	
31–60	54 (34)	4 (22)	13 (25)	37 (43)	
61–90	24 (15)	0 (0)	9 (17)	15 (17)	
91–323	19 (13)	3 (17)	8 (15)	8 (9)	
Infant gender, n (%)					.018
Male	80 (51)	13 (72)	31 (60)	36 (41)	
Female	77 (49)	5 (28)	21 (40)	51 (59)	
Maxillary tie, n (%)					.001
Yes	44 (44)	0 (0)	15 (42)	29 (56)	
No	55 (56)	11 (100)	21 (38)	23 (44)	
Multiple frenotomies, n (%)					.139
Yes	43 (27)	2 (11)	18 (35)	23 (26)	
No	114 (73)	16 (89)	34 (65)	64 (74)	
Mother sought breastfeeding consultation prior to frenotomy evaluation, n (%)					.092
Yes	153 (98)	16 (89)	51 (98)	86 (99)	
No	4 (3)	2 (11)	1 (2)	1 (1)	
Any maternal breastfeeding difficulties prior to frenotomy evaluation ^d , n (%)					.030
Yes	146 (93)	14 (78)	51 (98)	81 (93)	
No	11 (7)	4 (22)	1 (2)	6 (7)	
Any infant breastfeeding difficulties prior to frenotomy evaluation ^e , n (%)					.115
Yes	156 (99)	17 (94)	52 (100)	87 (100)	
No	1 (1)	1 (6)	0 (0)	0 (0)	

^a Pearson chi-square and, where appropriate, Fisher's Exact.^b Kruskal–Wallis.^c Mantel–Haenszel chi-square.^d i.e., “nipple skin damage and/or bleeding”, “misshapen nipple”, “compression/stripe mark on the nipple after breastfeeding”, “low milk supply”, “plugged ducts”, and/or “mastitis”.^e i.e., “latching issues”, “poor weight gain”, “weight loss”, “prolonged feedings”, “use of a bottle”, “chewing or lipsticking”, and/or “clicking sounds while nursing”.

Table 4
Respondents with no post-intervention maternal-infant breastfeeding difficulties.

Pre-intervention characteristic	Total	Ankyloglossia classification		
		Anterior (Type I and Type II)	Type III	Type IV
Infant latching difficulties, n (%)				
Yes	37 (51)	3 (100)	12 (48)	22 (49)
No	21 (95)	4 (80)	6 (100)	11 (100)
<i>p</i> ^a	<.001	.625	<.001	<.001
Maternal nipple pain, n (%)				
Yes	75 (64)	11 (79)	25 (60)	39 (63)
No	32 (97)	3 (100)	8 (100)	21 (95)
<i>p</i> ^a	<.001	.001	<.001	<.001

^a McNemar's test, exact version.

all other means to alleviate maternal pain and inefficient latch. Many infants were also “problematic bottle feeders”, that is, they entrained air, “clicked”, took longer than usual to feed, required considerable attention, and often could not keep a pacifier in their mouth [8]. Our study of this large, referred population produced findings that validate the efficacy of frenotomy among infants with ankyloglossia in reversing breastfeeding difficulties. Nearly all respondents reported that the frenotomy was worthwhile for their infant and themselves and only a minority of respondents (6%) reported negative emotional and/or physical side effects from the procedure.

Our study conclusively demonstrated that the symptoms of maternal pain and infant feeding dysfunction provoked by both anterior and posterior ankyloglossia, and which contributes to failure in breastfeeding, can be ameliorated by frenotomy. The relative importance of posterior ankyloglossia emerged as increasing numbers of infants were referred to us over time for persistent breastfeeding problems despite previous frenotomies of the anterior web, and were subsequently able to breastfeed after the posterior release. A limitation of previous studies incorporating randomization and sham frenotomy procedures is that pain reduction and feeding scores were assessed almost immediately post-intervention [10,11]. In our experience, improvements generally emerged over the week after the frenotomy and that gradual change was pronounced in older infants. This may reflect the muscle memory that infants must overcome.

The vast majority of infants referred to our practice had posterior rather than anterior ankyloglossia. Increasingly, physicians in our geographic area recognize and perform frenotomies on infants with anterior ankyloglossia. Unfortunately, most physicians are not yet familiar with the posterior variation and/or may be uncomfortable releasing the thicker Type III or the submucosal Type IV. Indeed, of the eight pediatric and neonatology providers trained by this pediatrician to perform frenotomies for posterior ankyloglossia, none have felt comfortable doing so. Recently, some local otorhinolaryngologists and oral surgeons/dentists intervene for the more problematic posterior ankyloglossia, either in the office or operating room.

Additionally, infants with posterior ankyloglossia were more likely than those with anterior ankyloglossia to have a maxillary tie. We were not able to differentiate the relative benefits to breastfeeding between sub-lingual and maxillary releases due to insufficient sample size.

We identified seven limitations to this study. There was likely a recall bias from a 52-month period surveyed over the final six months of the study. The pattern of referrals changed over time, trending toward younger infants and those with posterior ankyloglossia. Initially all referrals were from lactation consultants but changed to include providers from craniosacral, chiropractic, newborn nursery, and primary care practices. Maxillary tie and maxillary frenotomy was neither assessed for nor performed in the first few months of the intervention and only became a routine part

of the assessment after about two years. Despite the fact that exclusive breastfeeding was reported by nearly all respondents post-intervention, and the mean duration of breastfeeding was 14 months, we were unable to determine the effect of frenotomy on breastfeeding duration since our study did not include a control group. Our frenotomy technique was refined over time to cause fewer bleeding episodes and, in the last eleven months, parental instructions were incorporated to swipe the underside and lift the tongue after every infant feed for five days. This dramatically reduced the frequency of recurrent ties. The phenomenon of improvement then regression leading to a repeat frenotomy due to a restrictive scar has been noted by otorhinolaryngologists [19].

Lastly, the criteria for diagnosing a problematic ankyloglossia and maxillary tie were refined throughout the years to include the infant suck evaluation and more detailed feeding and family history questions. Only several infants referred to our practice did not meet criteria for ankyloglossia. This is likely because the vast majority of mothers reported having previously used and exhausted other types of interventions including lactation consultation by nurse and physician IBCLCs, craniosacral manipulation, naturopathic consultation, physical therapy, and anterior frenotomy. Among our cohort of infants with Type III or Type IV ankyloglossia, we were unable to predict risks for future articulation disorders since there is little in the speech or dental literature describing posterior ankyloglossia [20].

5. Conclusions

This study highlights the significance of maternal-infant breastfeeding difficulties associated with ankyloglossia, particularly posterior ankyloglossia, and demonstrates that a relatively simple, office-based procedure can safely lead to improved breastfeeding characteristics. Due to the increasing rates of breastfeeding one could make the argument that the diagnosis of ankyloglossia in infants should be a basic competency for all primary care providers. Treatment of anterior ankyloglossia is already becoming widespread, and access to regional otolaryngology, oral surgery, and dental providers with the experience and the special skills to perform posterior frenotomies will be important.

Conflict of interest

The authors report no financial and personal relationships with other people or organizations that could inappropriately influenced (bias) their work.

Role of the funding source

This study's sponsor, Middlesex Hospital, had no involvement in the study design, in the collection, analysis and interpretation of data; in the writing of the manuscript; and in the decision to submit the manuscript for publication.

Acknowledgements

We thank Betty Coryllos, MD, FACS, FAAP, IBCLC for clinical training on performing frenotomies, and Jennifer Tow, IBCLC, for lactation consulting and support in the early years of our intervention. We are grateful to the mothers and infants who participated in this study.

References

- [1] E. Coryllos, C. Watson Genna, A.C. Salloum, Congenital tongue-tie and its impact on breastfeeding, in: American Academy of Pediatrics, *Breastfeeding: Best for Baby and Mother*, 2004, 1–11.
- [2] I. Knox, Tongue tie and frenotomy in the breastfeeding newborn, *Neo Reviews* 11 (2010) e513–e519.
- [3] P. Hong, D. Lago, J. Seargeant, L. Pellman, A.E. Magit, S.M. Pransky, Defining ankyloglossia: a case series of anterior and posterior tongue ties, *Int. J. Pediatr. Otorhinolaryngol.* 74 (2010) 1003–1006.
- [4] J.L. Ballard, C.E. Auer, J.C. Khoury, Ankyloglossia: assessment, incidence, and effect of frenuloplasty on the breastfeeding dyad, *Pediatrics* 110(5)(2002) e63–e68.
- [5] A.K. Hazelbaker, *Tongue-Tie: Morphogenesis, Impact, Assessment and Treatment*, Aidan and Eva Press, Columbus, OH, 2010.
- [6] D.M. Griffiths, Do tongue ties affect breastfeeding? *J. Hum. Lact.* 20 (4) (2004) 409–414.
- [7] G.P. Forlenza, N.M. Paradise Black, E.G. McNamara, S.E. Sullivan, Ankyloglossia, exclusive breastfeeding, and failure to thrive, *Pediatrics* 125 (6) (2010) e1500–e1504.
- [8] M. Hogan, C. Westcott, M. Griffiths, Randomized controlled division of tongue-tie infants with breastfeeding problems, *J. Paediatr. Child Health* 41 (5–6) (2005) 246–250.
- [9] D. Geddes, D.B. Langton, I. Gollow, L.A. Jacobs, P.E. Hartmann, K. Simmer, Frenulotomy for breastfeeding infants with ankyloglossia: effects on milk removal and sucking mechanisms as imaged by ultrasound, *Pediatrics* 122 (2008) e188–e194.
- [10] M. Buryk, D. Bloom, T. Shope, Efficacy of neonatal release of ankyloglossia: a randomized trial, *Pediatrics* 128 (2011) 280–288.
- [11] S. Dollberg, E. Botzer, E. Grunis, F.B. Mimouni, Immediate nipple pain relief after frenotomy in breast-fed infants with ankyloglossia: a randomized, prospective study, *J. Pediatr. Surg.* 41 (2006) 1598–1600.
- [12] S. Dollberg, E. Botzer, Neo-natal tongue-tie: myths and science, *Harefuah* 150 (January (1)) (2011) 46–49, 67 (in Hebrew).
- [13] M. Martin, R. Schwartz, Tackling ankyloglossia in the office, *Contemp. Pediatr.* 25 (January (1)) (2008) 59–64.
- [14] L.H. Amir, J.P. James, J. Beatty, Review of tongue-tie releases at a tertiary maternity hospital, *J. Paediatr. Child Health* 41 (2005) 243–245.
- [15] M. Yeh, Outpatient division of tongue-tie without anesthesia in infants and children, *World J. Pediatr.* 4 (2008) 106–108.
- [16] American Academy of Pediatrics, American Academy of Pediatrics statement on breastfeeding and the use of human milk, *Pediatrics* 115 (2) (2005) 496–506.
- [17] U.S. Department of Health and Human Services, The Surgeon General's Call to Action to Support Breastfeeding, U.S. Department of Health and Human Services, Office of the Surgeon General, Washington, DC, 2011 <http://www.surgeongeneral.gov>.
- [18] Fifty-fourth World Health Assembly, Infant and Young Child Nutrition. World Health Assembly 54.2, Agenda item 13.1, 18 May 2001.
- [19] T. Klockars, A. Pitkaranta, Pediatric tongue-tie division: indications, techniques and patient satisfaction, *Int. J. Pediatr. Otorhinolaryngol.* 73 (2009) 1399–1401.
- [20] L. Kotlow, Diagnosis and treatment of ankyloglossia and tied maxillary fraenum in infants using Er:YAG and 1064 diode lasers, *Eur. Arch. Paediatr. Dent.* 12 (2011) 105–112.